

Changes of Femoral Bone Tissue Microstructure in Transgenic Rabbits

(transgenic rabbit / bone tissue / histomorphometry / femur / *hFVIII* gene)

M. MARTINIAKOVÁ¹, R. OMELKA², P. CHRENEK³, Ľ. RYBAN⁴, V. PARKÁNYI³,
B. GROSSKOPF⁵, M. VONDRÁKOVÁ¹, M. BAUEROVÁ²

¹Department of Zoology and Anthropology, ²Department of Botany and Genetics, Constantine the Philosopher University, Nitra, Slovakia

³Research Institute of Animal Production, Nitra, Slovakia

⁴Department of Vascular Biology and Thrombosis Research, Medical University, Vienna, Austria

⁵Institute of Zoology and Anthropology, Georg-August University, Göttingen, Germany

Abstract. Bone tissue microstructure of femur was investigated in transgenic New Zealand White rabbits with human factor VIII gene. Altogether 42 bones (24 from transgenic rabbits and 18 from non-transgenic ones) were analysed. Specimens were prepared using standard histological equipment, producing thin sections of approximately 80-100 µm. For histomorphometrical analysis areas, perimeters, minimum and maximum diameters of osteons' vascular canals and of osteons were measured. We found out that the basic structural pattern of femoral bone tissue was primary vascular longitudinal in both groups of rabbits. However, a new type of the bone tissue – fibrolamellar – was identified only in the transgenic rabbits. The measured variables of the osteons' vascular canals were higher in transgenic individuals in comparison with the non-transgenic ones (except for maximal diameter) and the differences were statistically significant ($P < 0.05$; $P < 0.01$). We suppose that the observed differences could be associated with transgenesis. In an effort to explain these differences we compared the cytogenetic profile of bone marrow cells between transgenic and non-transgenic rabbits. A significantly higher rate of aneuploidy was observed in c-metaphase spreads of transgenic individuals as compared to non-transgenic ones ($P < 0.001$). Despite the fact that no *hFVIII* mRNA expression was found in the femur of transgenic rabbits, we discussed an association of transgene integration into the genome and microstructural changes in the bone. In any case, the results indicate that transgenesis can also produce changes in other tissues than in the target ones.

The microscopic structure of rabbit long bones consists in general of primary vascular longitudinal bone tissue. The tissue is created by vascular canals of osteons which run in a direction essentially parallel to the long axis of the bone (Enlow and Brown, 1956). In some parts of the bone the concentration of osteons is quite dense (Martiniaková et al., 2003). Changes of the bone tissue microstructure between individuals of the same species are widely conditional to different age of the individuals (Kerley, 1969; Watanabe et al., 1998; Martiniaková et al., 2005), length of the investigated bone (Jowsey, 1966; Martiniaková, 2003) and also to genetic factors (Beamer et al., 2001).

The transgenic technology focusing on production of recombinant proteins of therapeutic value in the milk of mammals has been increasingly successful in recent years. For research purposes, transgenic rabbits offer an attractive alternative to large dairy animals because of their large litter size and short generation interval (Dove, 2000; Hiripi et al., 2003). Chrenek et al. (2005) generated transgenic rabbits with the human factor VIII gene, which encodes a protein with important therapeutic application for the treatment of haemophilia A. Using the gene construct (*WAP-hFVIII*) in case of integration should cause expression of the recombinant protein in the mammary gland only. On the other hand, a slight *hFVIII* mRNA expression was also found in the spleen, lung and brain of transgenic rabbits (unpublished results).

In general, it is accepted that a random integration of a transgene can disrupt the function or regulation of an endogenous gene, resulting in insertional mutations (Palmiter and Brinster, 1986) or chromosomal aneuploidy (Goepfert et al., 2000). Aneuploidy is the gain or loss of chromosomes as a result of meiotic and mitotic non-disjunction events, which can also lead to an altered gene balance and loss of heterozygosity (Goepfert et al., 2000). Parkányi et al. (2004) analysed transgenic rabbits with the *hFVIII* gene and they

Received July 18, 2005. Accepted September 12, 2005.

This study was supported from grant No. 2003 SP51/028 09 00/028 09 03 coordinated by the Slovak Academy of Sciences and from the UKF grant CGA VI/6/2004.

Corresponding author: Monika Martiniaková, Department of Zoology and Anthropology, Constantine the Philosopher University, Nábřežie mládeže 91, 949 74 Nitra, Slovakia. Tel.: (+421) 907 670 199; fax: (+421) 37 6511 008; e-mail: mmartiniakova@pobox.sk

observed a significantly higher rate of aneuploidy in c-metaphase spreads of peripheral blood lymphocytes in transgenic individuals (56–66%) as compared to non-transgenic ones (28–38%) ($P < 0.01$). No structural aberrations were revealed in either group.

The objective of this study was to compare femoral bone tissue microstructure between transgenic and non-transgenic rabbits and to discuss possible causes of the changes if they are present. Therefore, the cytogenetic profile of bone marrow cells and *hFVIII* gene expression in the *femur* were also investigated.

Material and Methods

Animals

Our research focused on 12 transgenic rabbits and 9 non-transgenic ones (control group). The age of the individuals was 77 days. In the experiment, we used New Zealand White transgenic rabbit offspring from F₁ generation which were obtained after breeding transgenic founders (*WAP-hFVIII* gene construct) with a non-transgenic rabbit of the same breed (Chrenek et al., 2005). DNA was isolated from ear tissue of newborn animals and PCR was used to detect integration of the *WAP-hFVIII* gene.

Histological analysis

Altogether 42 *femurs* (24 from transgenic rabbits and 18 from non-transgenic ones) were analysed. Each of the bones was sectioned at the midshaft of its diaphysis, where the compact bone is thick enough and provides a large area for study of the bone tissue microstructure. In total, 42 transversal sections of the *femur* diaphysis were cut. The obtained segments were macerated and degreased (Martiniaková et al., 2003). Later the samples were embedded in epoxy resin Biodur (Günter von Hagens, Germany). Transverse thin sections (80–100 µm) were prepared with a sawing microtome (Leitz 1600, Wetzlar, Germany) and affixed to glass slides with Eukitt (Merck, Darmstadt, Germany). The qualitative histological characteristics of the bone tissue were determined according to the international accepted classification (Enlow and Brown, 1956), the quantitative ones were assessed using the software Scion Image (Scion Corporation, Frederick, MD). We measured the following variables: area, perimeter, and the minimum and maximum diameter of osteons' vascular canals and also of osteons. The t-test was used to distinguish differences in quantitative histological characteristics of the *femur* between transgenic and non-transgenic rabbits.

Cytogenetic analysis

A sample of bone marrow cells for cytogenetic analysis was taken from transgenic and non-transgenic rabbits, as described by Parkányi et al. (1981). Bone marrow cells were briefly flushed from the diaphyses by TCM 199 (Gibco BRL, Burlington, ON). Cells were

resuspended and incubated for 4.30 h in TCM 199 + 0.25 µg/ml colcemid (Life Technologies, Gaithersburg, MD) at 37 °C. After cultivation for 45–50 min in a hypotonic treatment with potassium chloride (0.075 M) and fixations in modified Carnoy's solution (3 : 1, methanol : acetic acid), resuspended cells were spread on frozen glass microslides, air-dried, and stored unstained at room temperature, or stained for 10 min with 2% Giemsa solution. Stained microslides were viewed with a Leica microscope. The chromosomal analysis was carried out from chromosome microphotographs, using 50 c-metaphases for each rabbit according to the international standard for rabbits (Committee for the Standardized Karyotyping of the Domestic Rabbit, 1981). The χ^2 test was used to compare the chromosomal aneuploidy of bone marrow cells in transgenic and non-transgenic rabbits.

Analysis of gene expression

Total RNA from mammary gland and bone (including rests of bone marrow) was extracted using TRIzol Reagent (Invitrogen, Vienna, Austria) according to the manufacturer's protocol. The obtained RNA was subsequently treated with DNase I (Fermentas MBI, Vilnius, Lithuania) to remove the genomic DNA contamination. About 900 ng of such treated total RNA was reverse transcribed using the Gene Amp RNA PCR kit (Perkin Elmer, Boston, MA) and the presence/absence of *hFVIII* mRNA in the tissues of mammary gland and bone of transgenic and control rabbits was analysed using sense 5' – TGC CTG ACC CGC TAT TAC TC – 3' and antisense 5' – TGA GGT ACC AGC TTC GGT TC – 3' primers. For quantification, the following sense 5'- CTT TGC TGA CCT GCT GGA TT - 3' and antisense 5'- GCT TGA CCA AGG AAA GCA AG - 3' primers located in different exons of the rabbit *HPRT* gene, thus avoiding co-amplification of genomic DNA under the amplification protocol, were used. Real-time PCR was performed using LightCycler (Roche Molecular Biochemicals, Indianapolis, IN). All obtained PCR products were subsequently analysed by agarose gel electrophoresis.

Results

Histological analysis

The basic structural pattern of femoral bone tissue was primary vascular longitudinal in both groups of rabbits. This tissue formed the inner layer surrounding the medullary cavity and also the periosteal surface of the bones. In the middle part of *substantia compacta*, dense Haversian bone tissue occurred. In transgenic rabbits, a new type of the bone tissue – fibrolamellar – was identified around the osteons (Fig. 1). All in all 725 osteons' vascular canals and 210 osteons of transgenic and non-transgenic rabbits were measured. The results are shown in Table 1. All variables of vascular canals of

osteons had higher values in transgenic rabbits than in the non-transgenic ones. According to t-test the differences were statistically significant ($P < 0.05$; $P < 0.01$), except for maximum diameter. We noted higher values for area and minimum diameter of osteons than in non-transgenic rabbits, but significant differences were not observed. In non-transgenic rabbits, higher values of perimeter and maximum diameter of the osteons were recorded. The differences were statistically significant ($P < 0.001$).

Cytogenetic analysis

A significantly higher rate of aneuploidy cells from bone marrow was obtained in transgenic rabbits (62%) than in non-transgenic ones (37%) ($P < 0.001$). The results are shown in Table 2.

Analysis of gene expression

Previously, a slight hFVIII mRNA expression in the spleen, lung and brain of transgenic rabbits was reported. Non-specific production of recombinant protein in bone cells could affect their function with possible morphological changes. Therefore, we evaluated the expression of the transgene in bone tissue of transgenic rabbits. Messenger RNA was prepared from two different tissues and analysed by real-time PCR. As expected, hFVIII mRNA expression was confirmed in the mammary gland of transgenic rabbits (positive control). No hFVIII mRNA expression was found in the analysed bone (including rests of bone marrow) of transgenic rabbits. Non-transgenic samples were also negative (Fig. 2).

Table 1. Quantitative histological analysis of the bone tissue comparing transgenic and non-transgenic rabbits

Measured values	Rabbits	n	Variables	$\bar{x} \pm SD$
vascular canals of osteons	transgenic	407	area (μm^2)	$315.25 \pm 58.88^{++}$
			perimeter (μm)	$63.30 \pm 9.66^{++}$
			max.diameter (μm)	24.70 ± 5.24
			min.diameter (μm)	$7.45 \pm 1.76^+$
	non-transgenic	318	area (μm^2)	226.38 ± 73.13
			perimeter (μm)	48.01 ± 8.74
			max.diameter (μm)	23.70 ± 5.27
			min.diameter (μm)	7.43 ± 1.48
osteons	transgenic	127	area (μm^2)	8974.8 ± 1824.32
			perimeter (μm)	311.25 ± 34.55
			max.diameter (μm)	149.08 ± 24.25
			min.diameter (μm)	51.61 ± 9.57
	non-transgenic	83	area (μm^2)	8929.41 ± 2433.60
			perimeter (μm)	$464.29 \pm 73.23^{+++}$
			max.diameter (μm)	$223.79 \pm 47.69^{+++}$
			min.diameter (μm)	50.79 ± 9.71

\bar{x} – mean; SD – standard deviation; $P < 0.05$ (+); $P < 0.01$ (++); $P < 0.001$ (+++)

Table 2. Chromosomal analysis of transgenic and non-transgenic rabbits

Groups of rabbits		Normal (%) $2n = 44$	Aneuploidies $2n < 44$	Aneuploidies $2n > 44$	Polyploidies
transgenic	female 1-9-2	15 (30%) ^a	31	3	1
	male 1-9-1	17 (34%) ^b	28	4	1
	female 36-3	10 (20%) ^c	38	2	0
	male 36-5	12 (24%) ^d	33	4	1
non-transgenic	female N1	27 (54%) ^e	17	5	1
	male N2	30 (60%) ^f	15	5	0

^{a,b,c,d,v}_{e,f} difference is significant at $P < 0.001$

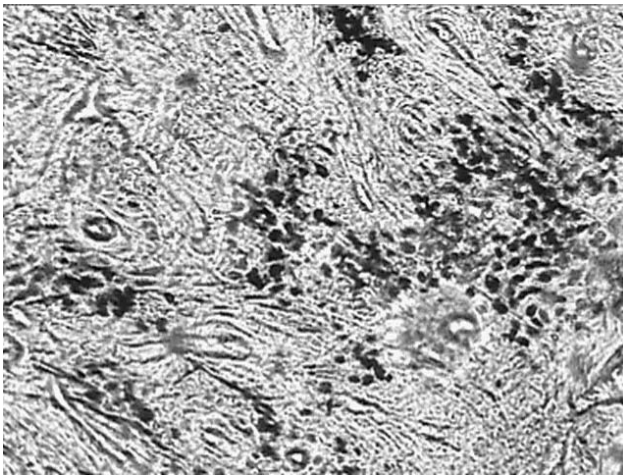


Fig. 1. Fibrolamellar bone tissue of transgenic rabbits

Discussion

Our results of the qualitative histological analysis (except for fibrolamellar bone tissue) are in complete agreement with Enlow and Brown (1958) and Martiniaková et al. (2003) studies. The basic structural pattern of femoral bone tissue was primary vascular longitudinal in both groups of rabbits. In the middle part of *substantia compacta*, dense Haversian bone tissue occurred. However, fibrolamellar bone tissue was found only in the transgenic rabbits according to our study. This tissue has not by now been identified in rabbits even in any ontogenetic stages. Currey (2002) noted that fibrolamellar bone tissue was found particularly in large mammals whose bones have to grow in diameter rather quickly.

The values of all measured variables in non-transgenic rabbits were comparable with the ones in the study by Martiniaková et al. (2003). The mean diameter of vascular canals (counted as the arithmetic mean of minimum and maximum diameter) in our non-transgenic individuals was higher than the one found by Müller and Demarez (1934). However, the authors did not mention breed and/or investigated bone in their study. Therefore, their results are only informative. Likewise, our value for the mean diameter of osteons was higher than those of Paaver (1973). In the available literature we failed to find comparable values for transgenic rabbits.

Microstructural differences between transgenic and non-transgenic rabbits were significant in many cases. It is not easy to find the real cause for the differences, since genetic and environmental factors should be taken into account. However, the animals were examined at the same age and they were kept under the same and standard conditions. We did not identify significant differences in femoral length between transgenic and non-transgenic rabbits. We suggest that evident differences, mainly in qualitative characteristics (presence of fibro-

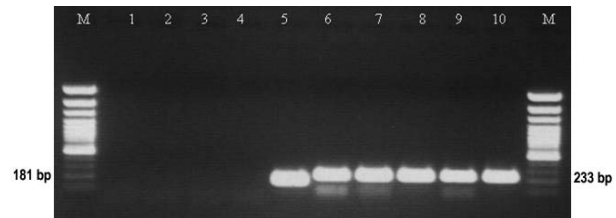


Fig. 2. Representative results of the WAP-hFVIII mRNA expression in the bone tissue of transgenic rabbits. Line M – marker (GeneRuler™, 100 bp DNA Ladder Plus, MBI Fermentas, Lithuania), lines 1, 2, 3 – bone tissue from transgenic rabbits, line 4 – bone tissue from non-transgenic rabbit, line 5 – mammary gland tissue from transgenic rabbit, lines 6, 7 and 8 – HPRT of bone tissue from transgenic rabbits, line 9 – HPRT of bone tissue from non-transgenic rabbit and line 10 – HPRT of mammary gland from transgenic rabbit

lamellar bone tissue in transgenic rabbits), could be associated with transgenesis. In general, there is a possibility that the observations could be caused by integration and expression of foreign DNA. However, the used gene construct with WAP promoter should cause expression of recombinant protein just in the mammary gland. The protein was not detected in bone according to our results. On the other hand, association between microstructural changes of femoral bone tissue and *hFVIII* gene integration cannot be denied. The transgene is usually randomly integrated into the genome in one or more copies. The integration could really affect the function of gene(s) located in the integration area including changes in the gene expression level, stability of the transcript or gene inactivation. However, if the transgene is integrated into regulation sequences (e.g. enhancers) or regulation genes, also other genes can be affected. In this case the effects of the integration could be very widespread, influencing genes located anywhere in the genome.

Chromosomal number instability can be a consequence of genetic manipulations. A low level of chromosomally abnormal cells is not thought to be detrimental, because these cells can be eliminated in early development or diverted to extraembryonic structures (Ward et al., 1993). Cytogenetic analysis of rabbit chromosomes from whole peripheral blood showed about 18% aneuploidies, while in rabbit bone marrow the frequency was about 35% (Parkányi, 1981). According to our results a significantly higher rate of aneuploidy was observed in c-metaphase spreads of bone marrow cells in transgenic individuals (62%) as compared to non-transgenic ones (37%) ($P < 0.001$). The same fact was observed in peripheral blood lymphocytes of transgenic rabbits (Parkányi et al., 2004). Although a higher frequency of numerical chromosomal aberrations did not show apparent deleterious effects on health or reproduction, we cannot eliminate their connection with microstructural changes in the *femur*.

In general, the molecular basis of bone tissue microstructure is not sufficiently documented. It has been reported that genetic makeup affects bone structure, development, and turnover. According to Havill (2003), heritability is an important component of bone physiology. Many studies using different models consistently demonstrate that, although environmental factors such as diet and exercise are important contributors to variability in bone microstructure, genetics plays a substantial role, with estimates of heritability ranging from 40 to 93% (Kelly et al., 1991; Beamer et al., 2001).

Genetically modified animals provide an alternative way to produce therapeutic proteins. However, several problems are commonly encountered with their production, including transgene integration, stability and expression. Our results indicate that transgenic technology can produce possible changes also in other tissues than in the target ones. On the other hand, the presence of the changes provides a possibility to study more details about the role of genetic and environmental factors in bone tissue formation.

References

- Beamer, W. G., Shultz, K. L., Donahue, L. R., Churchill, G. A., Sen, S., Wergedal, J. R., Baylink, D. J., Rosen, C. J. (2001) Quantitative trait loci for femoral and lumbar vertebral bone mineral density in C57BL/6J and C3H/HeJ inbred strains of mice. *J. Bone Miner. Res.* **16**, 1195-1206.
- Committee for standardized karyotype of the laboratory rabbit *Oryctolagus cuniculus*. (1981) Standard karyotype of the laboratory rabbit *Oryctolagus cuniculus*. *Cytogenet. Cell Genet.* **31**, 240-248.
- Currey, J. D. (2002) *Bones: Structure and Mechanisms*. Princeton University Press, New Jersey.
- Dove, A. (2000) Milking the genome for profit. *Nat. Biotechnol.* **18**, 1045-1048.
- Enlow, D. H., Brown, S. O. (1956) A comparative histological study of fossil and recent bone tissues. Part I. *Texas J. Sci.* **8**, 405-412.
- Enlow, D. H., Brown, S. O. (1958) A comparative histological study of fossil and recent bone tissues. Part III. *Texas J. Sci.* **10**, 210-211.
- Goepfert, T. M., McCarthy, M., Kittrell, F. S., Stephens, C., Ullrich, R. L., Brinkley, B. R., Medina, D. (2000) Progesterone facilitates chromosome instability (aneuploidy) in p53 null normal mammary epithelial cells. *FASEB J.* **14**, 2221-2229.
- Havill, L. M. (2003) Osteon remodeling dynamics in the Cayo Santiago Macaca mulatta: the effect of matriline. *Am. J. Phys. Anthropol.* **121**, 354-360.
- Hiripi, L., Makovics, F., Halter, R., Baranyi, M., Paul, D., Carnwath, J. W., Bösze, Z., Niemann, H. (2003) Expression of active human blood clotting factor VIII in the mammary gland of transgenic rabbits. *DNA Cell Biol.* **22**, 41-45.
- Chrenek, P., Rafay, J., Ryban, E., Makarevich, A., Bulla, J. (2005) Fertilizing capacity of transgenic and non-transgenic rabbit spermatozoa after heterospermic insemination. *Bull. Vet. Inst. Pulawy* **49**, 307-310.
- Jowsey, J. (1966) Studies of Haversian systems in man and some animals. *J. Anat.* **100**, 857-864.
- Kelly, P. J., Hopper, J. L., Macaskill, J. T., Pocock, N. A., Sambrook, P. N., Eisman, J. A. (1991) Genetic factors in bone turnover. *J. Clin. Endocrinol. Metab.* **72**, 808-813.
- Kerley, E. R. (1969) Age determination of bone fragments. *J. Forensic Sci.* **14**, 59-67.
- Martiniaková, M. (2003) Differences among species in microstructure of mammalian skeleton. Ph.D. Thesis, Nitra.
- Martiniaková, M., Vondráková, M., Fabiš, M. (2003) Investigation of the microscopic structure of rabbit compact bone tissue. *Scripta medica* **76**, 215-220.
- Martiniaková, M., Omelka, R., Chrenek, P., Vondráková, M., Bauerová, M. (2005) Age-related changes in histological structure of the femur in juvenile and adult rabbits: a pilot study. *Bull. Vet. Inst. Pulawy* **49**, 227-230.
- Müller, M., Demarez, R. (1934) Differential diagnostics of ape and human bone. *Med. Leg.* **14**, 498-560. (in French)
- Paaver, K. (1973) *Variability of osteonic organization in mammals*. Valgus, Tallin. (in Russian)
- Palmiter, R. D., Brinster, R. L. (1986) Germ-line transformation of mice. *Annu. Rev. Genet.* **20**, 465-499.
- Parkányi, V. (1981) Utilization of some methods of cytogenetic analysis in the detection of chromosome anomalies in the species *Oryctolagus cuniculus*. *Agriculture* **27**, 148-154.
- Parkányi, V., Chrenek, P., Rafay, J., Suvegová, K., Jurčík, R., Makarevich, A. V., Pivko, J., Hetényi, L., Paleyanda, R. K. (2004) Aneuploidy in the transgenic rabbit. *Folia Biol. (Praha)* **50**, 195-200.
- Ward, B. E., Gersen, S. L., Carelli, M. P., McGuire, N. M., Dackowski, W. R., Weinstein, M., Sandlin, C., Warren, R., Klinger, K. W. (1993) Rapid prenatal diagnosis of chromosomal aneuploidies by fluorescence *in situ* hybridization: clinical experience with 4,500 specimens. *Am. J. Hum. Genet.* **52**, 854-865.
- Watanabe, Y., Konishi, M., Shimada, M., Tsuji, H., Nishio, H., Suzuki, K., Iwamoto, S. (1998) Estimation of age from the femur of Japanese cadavers. *Acta Anat. Nippon* **73**, 33-41.